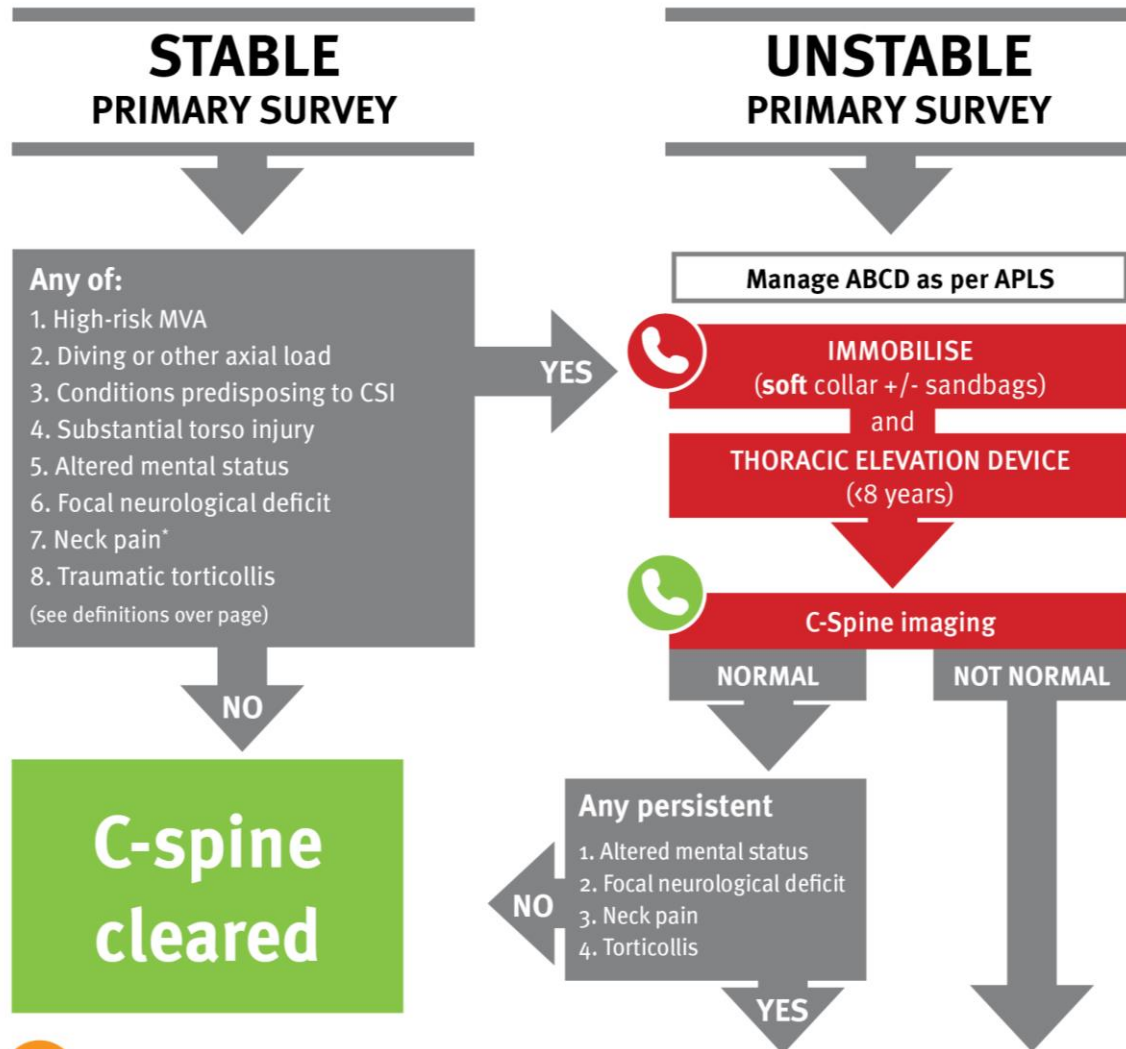


Queensland Paediatric Flowchart

Emergency

Cervical spine injury – Emergency management in children – Flowchart



Continue immobilisation

Seek urgent orthopaedic advice (onsite or via Retrieval Services Queensland (RSQ) on 1300 799 127) if suspect acute cervical facet joint dislocation (see over page) or spinal cord injury. Seek urgent paediatric critical care advice (onsite or via RSQ) for unstable child.

Seek senior orthopaedic advice as per local practice.

Seek senior emergency advice as per local practice. Consider contacting onsite/local orthopaedic service.

ALERT - Do **NOT** reposition a conscious child with traumatic torticollis unless there are airway concerns.

*Pain not tenderness. Asking children (where appropriate) where they are sore and assessing posture, mobility and clinical responses can help differentiate pain from tenderness. Consider initial period of observation prior to imaging if pain is sole risk factor identified.



C-spine injury risk factor definitions

- **High-risk MVA:**
 - head-on collision
 - rollover
 - ejection from vehicle
 - death in same crash
 - speed over 88kph
- **Substantial torso injury** = observable injuries that are life-threatening or warrant surgical intervention or inpatient observation
- **Altered mental status:**
 - GCS <15
 - AVPU <A
 - evidence of intoxication or other ALOC (e.g. disorientation, persistent anterograde amnesia, delayed or inappropriate response to external stimuli)
- **Diving or other axial load** = falling and landing head first from a height
- **Conditions predisposing to CSI:**
 - Down syndrome
 - Klippel-Feil syndrome
 - Achondroplasia
 - Mucopolysaccharidosis
 - Ehlers-Danlos syndrome
 - Marfan syndrome
 - osteogenesis imperfecta
 - Larsen syndrome
 - juvenile rheumatoid arthritis
 - juvenile ankylosing spondylitis
 - renal osteodystrophy
 - rickets
 - history of CSI or surgery
- **Focal neurological deficit:**
 - paraesthesia
 - loss of sensation
 - motor weakness
 - other neurologic finding consistent with spine injury (e.g. priapism)
- **Traumatic torticollis** includes difficulty moving the neck noted in history or physical examination. If no other indications for imaging, test rotation of neck, and proceed to immobilisation and imaging if unable to rotate to 45° bilaterally



ALERT – Hard collars are **not** recommended.

There is no evidence of efficacy and they may contribute to raised intracranial pressure, respiratory disturbance, patient agitation, and soft tissue ulceration.

C-spine imaging

Initial choice of imaging (CT vs plain films) is based on the likelihood of C-spine injury with considerations of radiation risks (higher in younger children) and potential need for sedation +/- transfer. Refer to the Guideline for more information.

Acute cervical facet joint dislocation

Maintain a high index of suspicion for acute cervical spine instability in a seat-belt restrained infant involved in a high force rapid deceleration injury, even if initial imaging appears normal.

Suspect acute cervical facet joint dislocation in the older, conscious child who presents with:

- history of a hyperflexion and loading injury e.g. rugby scrum collapse and
- abnormal focal neurology suggestive of cord injury

Acute facet joint dislocation with neurological signs is a time-critical emergency. Urgent definitive treatment (traction and/or surgical reduction) is required.

